

LIDIA: Precise Liver Tumor Diagnosis on Multi-Phase Contrast-Enhanced CT via Iterative Fusion and Asymmetric Contrastive Learning

Wei Huang^{1,2,3}, Wei Liu^{2,3}, Xiaoming Zhang^{2,3}, Xiaoli Yin⁴, Xu Han⁵,
Chunli Li^{2,3,4}, Yuan Gao^{2,3}, Yu Shi⁴, Le Lu², Ling Zhang², Lei Zhang¹, and
Ke Yan^{2,3}

¹ College of Computer Science, Sichuan University, 610065, Chengdu, China.

² DAMO Academy, Alibaba Group

³ Hupan Lab, 310023, Hangzhou, China

⁴ Department of Radiology, Shengjing Hospital of China Medical University,
Shenyang, 110004, China

⁵ Department of Hepatobiliary and Pancreatic Surgery, First Affiliated Hospital of
Zhejiang University, 310006, Hangzhou, China

zxiaoming360@gmail.com; leizhang@scu.edu.cn;

1 Appendix

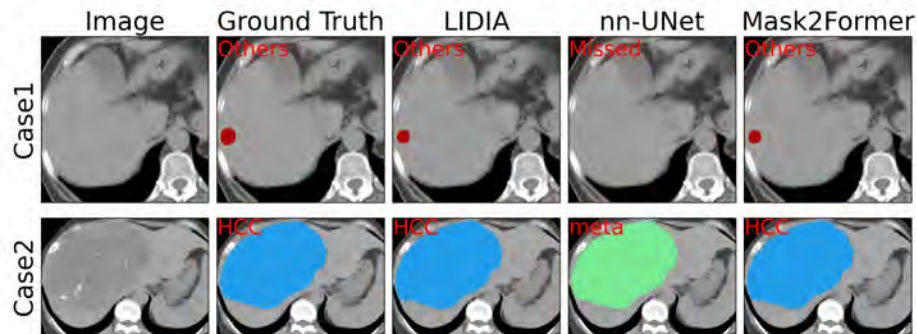


Fig. 1. Qualitative examples of lesion segmentation and classification in DCE-CT using different methods.

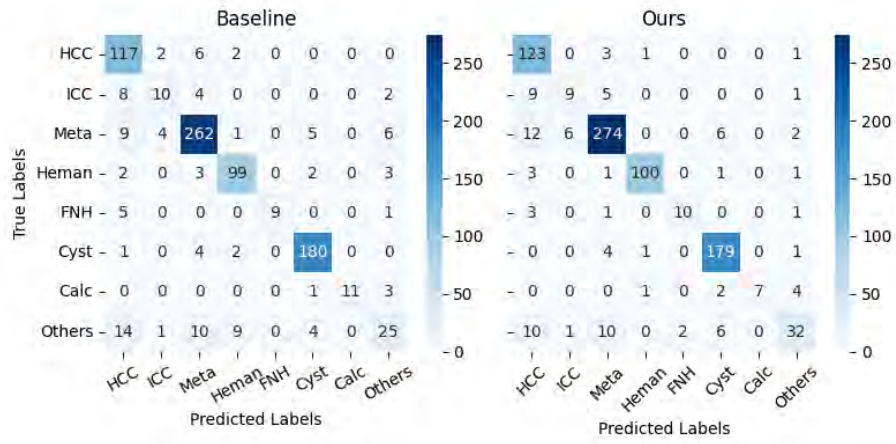


Fig. 2. Confusion matrix of lesion-level tumor classification in DCE-CT for recalled samples.